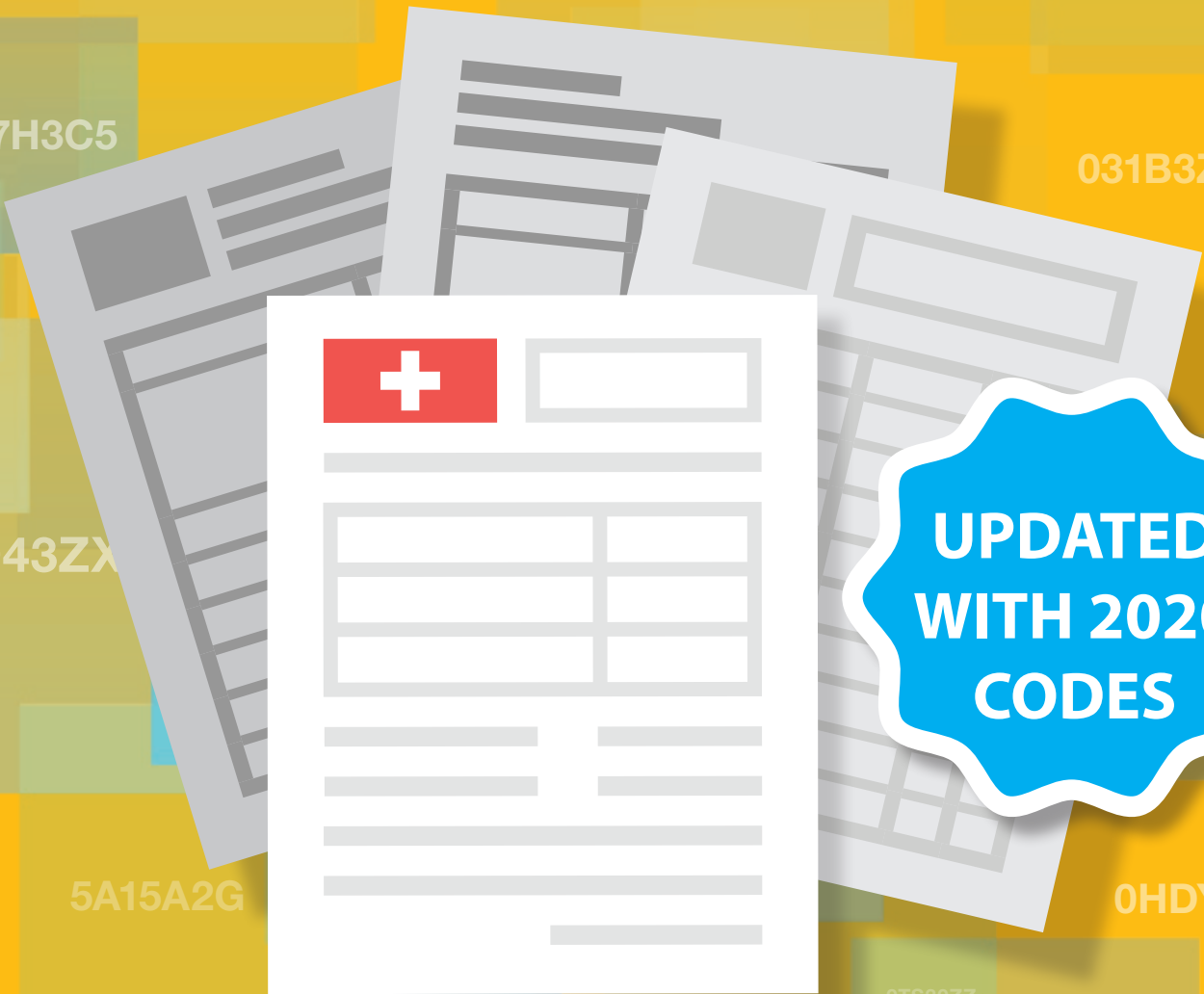


JustCoding

Clinical Scenario Workbook

2020 ICD-10-PCS Edition



Reviewed by

Shannon McCall, RHIA, CCS, CCS-P, CPC, CEMC, CRC, CCDS, CCDS-O, HCS-D
Adrienne Commeree, CPC, CPMA, CCS, CEMC, CPIP

07JT0ZZ

Clinical Scenario Workbook

2020 ICD-10-PCS Edition

Reviewed by

Adrienne Commeree, CPC, CPMA, CCS, CEMC, CPIP

Shannon McCall, RHIA, CCS, CCS-P, CPC, CEMC, CRC, CCDS, CCDS-O, HCS-D

JustCoding

HCPPro
a Simplify *Compliance* brand

JustCoding's Clinical Scenario Workbook: 2020 ICD-10-PCS Edition is published by HCPro, a Simplify Compliance brand.

Copyright © 2020 HCPro

All rights reserved. Printed in the United States of America.

ISBN: 978-1-68308-993-3

Product Code: JCCSICD10P20

No part of this publication may be reproduced, in any form or by any means, without prior written consent of HCPro or the Copyright Clearance Center (978-750-8400). Please notify us immediately if you have received an unauthorized copy.

HCPro provides information resources for the healthcare industry.

HCPro is not affiliated in any way with The Joint Commission, which owns the JCAHO and Joint Commission trademarks.

Amanda Norris, Editor

Adrienne Trivers, Product Manager

Matt Sharpe, Senior Manager, Creative Layout

Advice given is general. Readers should consult professional counsel for specific legal, ethical, or clinical questions.

Arrangements can be made for quantity discounts. For more information, contact:

HCPro

100 Winners Circle, Suite 300

Brentwood, TN 37027

Telephone: 800-650-6787 or 781-639-1872

Fax: 800-639-8511

E-mail: customerservice@hcpro.com

Visit HCPro online at www.hcpro.com and www.hcmarketplace.com



Table of Contents

About the Contributors	vii
About the Reviewers	ix
Introduction.....	xi
Chapter 1: Central Nervous System.....	1
Case 1: Craniotomy	3
Case 2: Evacuation of Subdural Hematoma.....	9
Central Nervous System Answers.....	13
Chapter 2: Heart and Great Vessels.....	19
Case 1: Coronary Angiography	21
Case 2: Aortic Valve Replacement	27
Case 3: CABG With AtriClip	31
Case 4: Transcatheter Aortic Valve Replacement	39
Case 5: Multiple CABG	43
Case 6: Placement of Port-A-Cath	47
Heart and Great Vessels Answers.....	51
Chapter 3: Upper Arteries	65
Case 1: Carotid Endarterectomy	67
Case 2: Subclavian Artery Stenting	69
Case 3: Right Carotid Endarterectomy	71
Upper Arteries Answers.....	75
Chapter 4: Lower Arteries.....	81
Case 1: Aortic Aneurysm Repair	83
Case 2: Coil Embolization	87
Case 3: Artery Bypass Graft	91
Case 4: Coronary Angiogram	93
Case 5: Stent Graft Placement	97
Lower Arteries Answers.....	101

Chapter 5: The Eye	107
Case 1: Lens Implantation	109
Case 2: Eyelid Sutures	113
The Eye Answers	115
Chapter 6: Gastrointestinal System.....	119
Case 1: Gastric Bypass	121
Case 2: Gastrectomy	127
Case 3: Lysis of Adhesions	129
Case 4: EGD	133
Case 5: Exploratory Laparotomy/Colectomy	139
Case 6: Sigmoid Colectomy	143
Gastrointestinal System Answers	147
Chapter 7: Hepatobiliary System and Pancreas	159
Case 1: Fluoroscopic Exchange.....	161
Case 2: Cholecystectomy	163
Hepatobiliary System and Pancreas Answers	165
Chapter 8: Skin and Breast	169
Case 1: Breast Reconstruction	171
Case 2: Partial Mastectomy	175
Skin and Breast Answers.....	177
Chapter 9: Upper Joints	181
Case 1: Cervical Interbody Fusion	183
Case 2: Shoulder Arthropathy	189
Case 3: Spinal Fusion	193
Upper Joints Answers	197
Chapter 10: Lower Joints	203
Case 1: Spinal Fusion	205
Case 2: Thoracolumbar Interbody Fusion	209
Case 3: Total Knee Arthroplasty	213
Case 4: Fusion	217
Case 5: Hardware Removal.....	223
Lower Joints Answers	225

Chapter 11: Female Reproductive System	235
Case 1: Laparoscopic Hysterectomy	237
Case 2: Total Abdominal Hysterectomy.....	241
Case 3: Endometrial Curetting	249
Case 4: Hysterectomy With Suburethral Sling.....	251
Female Reproductive System Answers	255
Chapter 12: Male Reproductive System.....	263
Case 1: Resection of Prostate	265
Case 2: Scrotal Exploration	269
Male Reproductive System Answers.....	275
Chapter 13: Pregnancy	279
Case 1: Dilation and Curettage	281
Case 2: Cesarean Section	285
Case 3: Vaginal Delivery	289
Pregnancy Answers.....	293
Chapter 14: Miscellaneous Cases	299
Case 1: Left Heart Catheterization	301
Case 2: Femur Reposition	305
Case 3: Excisional Debridement.....	309
Case 4: Debridement of Abscesses.....	313
Case 5: Bronchoscopy.....	315
Case 6: Transurethral Resection.....	319
Case 7: Debridement and Adjacent Tissue Transfer	323
Miscellaneous Cases Answers	327



About the Contributors

Julie Boomershine, RHIA, CCS, CTR, CHDA

Julie Boomershine, RHIA, CCS, CTR, CHDA, AHIMA-approved ICD-10 trainer, manager of coding operations at HRS in Baltimore, Maryland, has more than 20 years of experience in HIM. She holds an associate's degree in HIM from Davenport University in Kalamazoo, Michigan, and a bachelor's degree in HIM from the University of Cincinnati. Since 2015 Julie has served as HRS' manager of coding operations, liaising with clients and providing expertise to the coding team to elevate its delivery of excellence.

Stacie L. Buck, RHIA, CCS-P, RCC, CIRCC

Stacie L. Buck, RHIA, CCS-P, RCC, CIRCC, AAPC Fellow, is president and senior consultant for RadRx of Stuart, Florida, and provides coding, auditing, and education services for diagnostic and interventional radiology service providers on a nationwide basis. Buck has 25 years' experience in healthcare, 17 of those in radiology. She is a nationally sought-out speaker who has presented over 200 coding seminars. She also is the author of the coding reference books *Cracking the IR Code: Your Comprehensive Guide to Mastering Interventional Radiology Coding* and *Cracking the IR Code: Mastering Interventional Radiology Coding Comprehensive Online Training Program*.

Ghazal Irfan, MBI, RHIA

Ghazal Irfan, MBI, RHIA, is the coding compliance manager of hospital services for Cerner RevWorks-Adventist Health. Irfan works with her team to ensure revenue cycle compliance. Irfan holds a master's degree in biomedical informatics from Oregon Health and Science University, a degree in HIM, and a master certificate in population health, value-based purchasing, and data analytics from Johns Hopkins. Irfan also writes for various publications, including HCPro's newsletter *Briefings on Coding Compliance Strategies*.

Jonathan LaFleur, BSN, RN, CCS

Jonathan LaFleur, BSN, RN, CCS, senior auditing and clinical specialist at HRS in Baltimore, Maryland, has more than 16 years of healthcare experience, both at the bedside and in HIM. Prior to joining HRS, LaFleur worked in several emergency departments and as a charge nurse in the medical ICU at a Level I teaching hospital. He has since worked in clinical documentation improvement (CDI) as both a CDI specialist and analyst, and he has performed audits for hospitals throughout the country.

Laura Legg, RHIT, RHIA, CCS, CDIP

Laura Legg, RHIT, RHIA, CCS, CDIP, is the director of revenue integrity solutions at BESLER located in Princeton, New Jersey. Legg has more than 25 years of experience in HIM, including critical access hospitals, large hospitals, and a major health system.

Shannon E. McCall, RHIA, CCS, CCS-P, CPC, CEMC, CRC, CCDS, CCDS-O, HCS-D

Shannon E. McCall, RHIA, CCS, CCS-P, CPC, CEMC, CRC, CCDS, CCDS-O, HCS-D, is the director of HIM and coding for HCPro, a Simplify Compliance brand, in Middleton, Massachusetts. She oversees all of the Certified Coder Boot Camp programs. McCall developed the Certified Coder Boot Camp®—Inpatient Version, the Evaluation and Management Boot Camp™, and most recently collaborated with the CDI team on the Risk Adjustment Documentation and Coding Boot Camp™. McCall works with hospitals, medical practices, and other healthcare providers on a wide range of coding-related custom education sessions.

Lori-Lynne Webb, CPC, CCS-P, CCP, CHDA, CDIP, COBGC

Lori-Lynne Webb, CPC, CCS-P, CCP, CHDA, CDIP, COBGC, AHIMA-approved ICD-10-CM/PCS trainer, is an E/M and procedure-based coding, compliance, data charge entry, and HIPAA privacy specialist based out of Melba, Idaho, with more than 20 years of experience. Webb's coding specialty is OB/GYN office/hospitalist services, maternal fetal medicine, OB/GYN oncology, urology, and general surgical coding.



About the Reviewers

Adrienne Commeree, CPC, CPMA, CCS, CEMC, CPIP

Adrienne Commeree, CPC, CPMA, CCS, CEMC, CPIP, serves as a regulatory specialist for HCPro, teaching the Certified Coder Boot Camp® programs. She is an instructor with extensive knowledge of inpatient and outpatient coding guidelines as well as E/M and auditing guidelines. She has many years of experience in the healthcare industry, including coding, auditing, training, and compliance expertise.

Shannon E. McCall, RHIA, CCS, CCS-P, CPC, CEMC, CRC, CCDS, CCDS-O, HCS-D

Shannon E. McCall, RHIA, CCS, CCS-P, CPC, CEMC, CRC, CCDS, CCDS-O, HCS-D, is the director of HIM and coding for HCPro. She oversees all of the Certified Coder Boot Camp programs. McCall developed the Certified Coder Boot Camp®—Inpatient Version, the Evaluation and Management Boot Camp™, and most recently collaborated with the CDI team on the Risk Adjustment Documentation and Coding Boot Camp™. McCall works with hospitals, medical practices, and other healthcare providers on a wide range of coding-related custom education sessions.



Introduction

JustCoding's Clinical Scenario Workbook: 2020 ICD-10-PCS Edition contains 52 sample clinical cases to provide hands-on reinforcement of coding concepts. The cases range in difficulty, length, and medical specialty. They are designed to simulate real-life coding processes for training and assessing new coders or keeping skills sharp for experienced staff.

Each case includes operative reports based on real clinical scenarios. Cases offer a variety of documentation styles to reflect inconsistencies between different electronic health record systems and providers.

After reviewing the cases, coders should report the most applicable ICD-10-CM diagnosis codes and all relevant ICD-10-PCS procedure codes. Answer keys are included at the end of each chapter with the correct codes to report for each case. The answer keys were reviewed by HCPro's coding instructors and include:

- A list of reportable ICD-10-CM and ICD-10-PCS codes, as well as rationale for using those codes
- Applicable coding guidance, where appropriate, including references from the *2020 ICD-10-CM* and *2020 ICD-10-PCS Official Guidelines for Coding and Reporting* and the AHA's *Coding Clinic*
- Instructions for looking up ICD-10-CM codes and certain ICD-10-PCS codes in the coding manuals

All codes and guidance have been reviewed and are up to date as of October 1, 2019. The ICD-10-CM and ICD-10-PCS code sets as well as any guidance are subject to changes. These cases therefore should not be used as a guide for coding any real claims.

TS30ZZ

0L950ZX

Central Nervous System

0LWX07Z

0FBD3ZZ

0RP503Z

0L5J4Z

G3ZZ

01B20ZX

00T70ZZ

0TS30ZZ

07JT0



Case 1: Craniotomy

Discharge summary:

Admitting diagnosis: Ataxia, nystagmus, vomiting. R/O head injury.

Discharge diagnosis: Grade 1 Ependymoma of the cerebellum, left flaccid hemiparesis, cerebellar ataxia due to neoplasm.

Procedures:

MRI, PET, Myelogram, Craniotomy

History of present illness:

Seven-year-old Hispanic male brought to ED by his mother with a two-day history of poor coordination, falls, and irritability. Today she noticed his eyes were “moving funny” and he began vomiting.

Past medical history:

Chronic otitis media, bilateral myringotomy and tubes at age 2.

Allergies:

Amoxicillin, Biaxin

Hospital course:

Unremarkable

Disposition:

Home

Discharge condition:

Stable

Discharge medications:

None

Discharge instructions:

Diet as tolerated. Tylenol for pain. Post op check in Neurosurgical Clinic in one week. Appointment with Pediatric Oncology Team in 3 days.

Emergency department:

Chief complaint: New onset clumsiness and repeated falls. Irritability and vomiting, unusual eye movements.

HPI: Patient was in his usual state of good health until 2 days ago. Mother noticed he was tripping and falling and seemed to drag his left leg. He denied pain, just said his left side felt “heavy” and was not “working right.” This morning he refused breakfast and then began vomiting. Mother noticed his eyes were moving very quickly from side to side. She asked a neighbor to drive them to the hospital.

Assessment/Plan: MRI to R/O head injury. Admit to Peds Floor.

Admission history and physical:

Chief complaint: Vomiting, left side weakness and poor coordination

History of present illness: Patient describes feeling like his left side was “heavy” two days ago and that he fell down a lot when he was playing soccer. He does not recall striking his head when he fell. He denies pain. When he woke this morning, his stomach felt upset so he refused breakfast and watched some TV. He had trouble focusing on the TV because his eyes were “moving funny” and then he suddenly began vomiting.



Case 2: Evacuation of Subdural Hematoma

Preoperative diagnosis:

Large right cerebral convexity from nontraumatic acute and chronic subdural hematoma

Postoperative diagnosis:

Large right cerebral convexity from nontraumatic acute and chronic subdural hematoma

Operative procedure: right frontoparietal craniotomy, evacuation of subdural hematoma, placement of subdural drain to suction bulb

Surgeon: Neurosurgeon, MD

Anesthesia: General endotracheal

Prep: Iodine Povacrylex and isopropyl alcohol

Description of the procedure:

The patient presented to the operating room. After satisfactory induction of general endotracheal anesthesia, the patient was positioned supine on the operating table. A shoulder bolster was placed to facilitate positioning and 3-point fixation was applied to the skull. The head was gently rotated to the left and the head secured to the operating table with a Mayfield adaptor. The arms were tucked by the sides. All bony prominences were padded. He had a free-flowing peripheral IV and was monitored with electro-cardiogram, Telemetry, pulse oximetry, a temperature probe, and a radial arterial line. Clindamycin 900 mg intravenous was given prior to the incision. The right side of the scalp was shaved with an electric razor and then the skin prepped and draped sterilely. 0.5% Bupivacaine HCl with 1:200,000 units epinephrine was infiltrated locally, a total of approximately 30 cc for the entire case.

A standard curvilinear incision was made on the right side, extending just in front of and above the right ear and then posteriorly into the parietal region and then anteriorly toward the frontal region along the mid-pupillary line. Dissection was carried down with cautery and galeal bleeders controlled with cautery, bipolar cautery, and Raney clips. The temporalis fascia muscle was also incised with cautery and then the skin flap and muscle reflected as a single unit inferiorly and held open with fishhooks. Three burr holes were placed. The dura mater was stripped with a #1 and #3 Penfield. A right frontoparietal bone flap was then elevated with the craniotome without difficulty. Circumferential dural tack-up sutures were applied. The dura mater was opened with #15 blade scalpel and then with dural scissors. There was acute on chronic subdural blood, which was released with suction and irrigation. No obvious point sources of bleeding were identified and the subdural compartment at this point appeared dry. The brain was pulsatile and did start to slightly expand, although there was still some indentation at the time of closure. I placed a round #10 French fluted drain in the subdural space and brought it out through a separate trocar incision posterior to the parietal burr hole. This was later connected to a sterile suction bulb and secured to the skin with 2-0 silk. The dura mater was then closed with a running 4-0 Nurolon. Dural regeneration matrix was also left in the epidural space. A central tack-up suture was also applied and then the bone flap was secured with two medium-sized burr hole covers, one that would allow a drain to come out of the parietal burr hole and also a square connector and multiple 4 mm Walter Lorenz screws. The temporalis fascia and muscle were reapproximated with simple interrupted 0 Vicryl. The Raney clips were removed. The skin flap was then closed in several layers using inverted interrupted 2-0 Vicryl for the galea and staples for the skin. The wound was dressed sterilely. All counts were correct x2. Estimated blood loss was 250 cc and none was replaced. There were no immediate complications. Three-point fixation was removed and the patient was transferred to the recovery room in stable condition.

Codes:

ICD-10-CM:

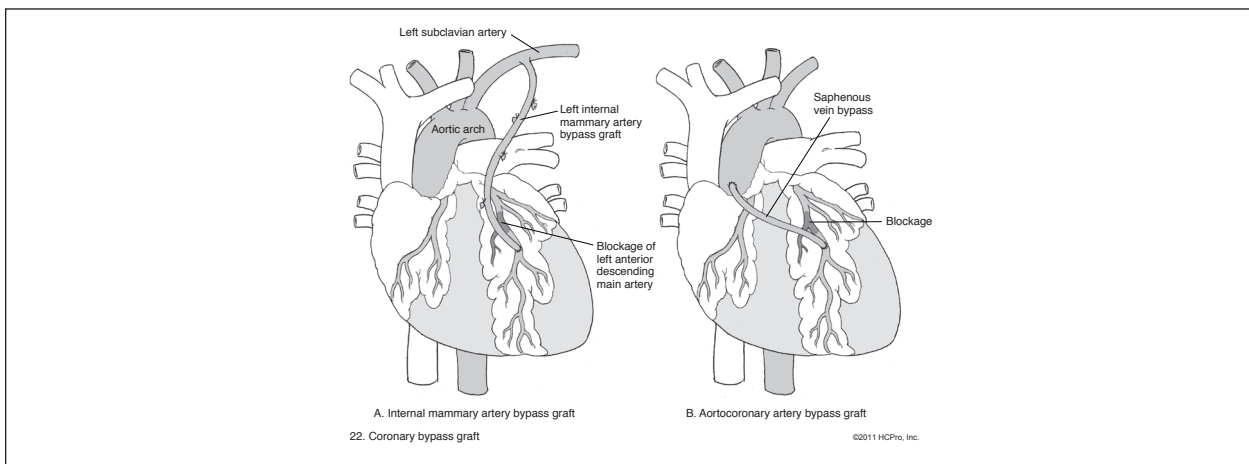
ICD-10-PCS:

NOTES



Case 3: CABG With AtriClip

FIGURE 2.1 Thromboendarterectomy



Preoperative diagnoses:

1. Triple vessel coronary artery disease
2. Unstable angina
3. Hypertension
4. Hyperlipidemia
5. Obesity

Postoperative diagnoses:

1. Same

Operative procedure:

1. Quintuple vessel coronary artery bypass grafting procedure with left internal mammary artery to left anterior descending coronary artery

Chapter 2

2. Separate aortic-based reversed saphenous vein graft sequenced to posterior descending artery and posterior lateral artery
3. Separate aortic-based reversed saphenous vein graft to distal circumflex
4. Separate aortic-based radial artery graft to obtuse marginal vessel
5. Ligation of left atrial appendage with 35 mm AtriClip®
6. Endoscopic harvest of the left radial artery
7. Endoscopic harvest of greater saphenous vein of the left lower extremity
8. Insertion of intra-aortic balloon pump

Anesthesia: General endotracheal

Skin prep: Povidone-iodine and iodine povacrylex with isopropyl alcohol

Incisions: Median sternotomy and endoscopic incisions overlying the greater saphenous vein of the left lower extremity and endoscopic incision overlying the left radial artery

Drains: Two French 32 Argyle chest tubes, mediastinal, and Blake 19 left pleural tube

Closure: Routine

Cross-clamp time: 172 minutes

Bypass time: 193 minutes

Estimated blood loss: 989 CC

Urine output: 1650 CC

Complications: None

Condition: Critical

TS30ZZ

0L950ZX

0LWX07Z

Heart and Great Vessels Answers

0FBD3ZZ

0RP503Z

0L5J4Z

G3ZZ

01B20ZX

00T70ZZ

0TS30ZZ

07JT0

Answers for Case 1: Coronary Angiography

ICD-10-CM codes:

I22.1, subsequent type 1 ST elevation (STEMI) myocardial infarction of inferior wall

I21.02, type 1 ST elevation (STEMI) myocardial infarction involving left anterior descending coronary artery

I10, essential (primary) hypertension

E78.5, hyperlipidemia, unspecified

E66.3, overweight

Z95.5, presence of coronary angioplasty implant and graft

Z91.19, noncompliance with other medical treatment and regimen

ICD-10-PCS codes:

027034Z, Dilation of the coronary artery, one artery with drug-eluting intraluminal device, using a percutaneous approach

B211YZZ, Fluoroscopy of multiple coronary arteries using other contrast

Rationale:

The patient was admitted for treatment of a second ST elevation acute type 1 MI at a different site from an ST elevation acute type 1 MI three weeks prior. STEMIs are myocardial infarctions that show ST-segment changes on electrocardiogram (ECG or EKG). ST elevation usually reflects acute thrombotic coronary occlusion. STEMI generally involves the myocardium from the epicardium to endocardium. Non-ST elevation myocardial infarctions (NSTEMI) don't show any ST-segment changes and usually don't involve the whole thickness of myocardium.

When a patient who suffered an acute myocardial infarction (AMI) has a new AMI within 4 weeks of the initial AMI, a code from category I22.- (subsequent ST elevation [STEMI] and non-ST elevation [NSTEMI] myocardial infarction) must be used in conjunction with a code

from category I21.- (ST elevation [STEMI] and non-ST elevation [NSTEMI] myocardial infarction). The sequencing of the I22.- and I21.- codes depends on the circumstances of the encounter. In this case, the subsequent AMI is the reason for the admission so the code from category I22.- is sequenced first. ICD-10-CM codes in category I21.- (initial AMI) and category I22.- (second AMI) describe the specific site. Do not assign code I22.- for subsequent myocardial infarctions other than type 1 or unspecified. There is a code block level instructional note for ischemic heart diseases (I20-I25) directing the coder to assign an additional code to identify presence of hypertension (I10-I15).

The essential hypertension and hyperlipidemia are addressed during the current episode of care and are coded additionally. The documentation indicates that the patient is overweight and this is also coded. BMI is not documented so an additional code for BMI cannot be assigned. A Z-code is assigned to identify the presence of the stent that was placed during the previous episode of care and another Z-code is assigned to capture the patient's noncompliance with the treatment regimen.

The ICD-10-CM Official Guidelines for Coding and Reporting state that the circumstances of inpatient admission always govern the selection of principal diagnosis. The principal diagnosis is defined in the Uniform Hospital Discharge Data Set (UHDDS) as “that condition established after study to be chiefly responsible for occasioning the admission of the patient to the hospital for care.”

For reporting purposes, the definition for “other diagnoses” is interpreted as additional conditions that affect patient care in terms of requiring: clinical evaluation, or therapeutic treatment, or diagnostic procedures, or extended length of hospital stay, or increased nursing care and/or monitoring. The UHDDS item #11-b defines Other Diagnoses as “all conditions that coexist at the time of admission, that develop subsequently, or that affect the treatment received and/or the length of stay. Diagnoses that relate to an earlier episode which have no bearing on the current hospital stay are to be excluded.”

Acute myocardial infarction:

The ICD-10-CM codes for acute myocardial infarction (AMI) identify the site, such as anterolateral wall or true posterior wall. Subcategories I21.0-I21.2 and code I21.3 are used for ST elevation myocardial infarction (STEMI). Code I21.4 (non-ST elevation (NSTEMI) myocardial infarction) is used for NSTEMI and nontransmural MIs.



Case 1: Aortic Aneurysm Repair

Preoperative diagnosis:

Abdominal aortic aneurysm (AAA)

Postoperative diagnosis:

AAA, right renal artery stenosis

Operations performed:

1. Endovascular repair of abdominal aortic aneurysm using fenestrated endograft system, Cook Z-Fen stent graft system
2. Reduction of a sliding inguinal hernia
3. Balloon angioplasty of right renal artery

Anesthesia:

General

Complications:

None

Procedure:

The patient was brought to the operative room. He underwent general anesthesia. The abdomen and lower extremities were prepped and draped in sterile fashion. Both femoral vessels were exposed through transverse bilateral inguinal incisions. There was a fairly large sliding hernia in the inguinal area with the hernia sac extending over the common femoral artery. Both femoral vessels were then exposed and circumferentially controlled proximally and distally. Both sides were then cannulated in retrograde fashion. There was a significant amount of tortuosity involving the iliac arteries.

We advanced a 6-French sheath on the left side, which was chosen as the contralateral side for delivery purposes. A Lunderquist stiff wire was advanced, allowing the iliac system to straighten out. At this time, we placed a 20-French Cook sheath in the left iliac system without difficulty. We proceeded to cannulate the hub of the 20-French sheath on the left side and successfully cannulated both renal arteries, placing a Rosen wire into the left renal artery without difficulty. There was stenosis at the origin of the right renal artery. This was cannulated and balloon angioplasty performed of the origin of the right renal artery using a 5x20 mm Viatrac balloon. In a similar fashion, Rosen wire was left in the right renal artery for marking purposes.

The main body of the device was chosen and had been designed using the patient's CT scan. There were two small fenestrations for each renal vessel with a scallop for the superior mesenteric artery. The graft diameter was 30 mm and it was two main body stents. This was oriented and successfully advanced. The device was then deployed using aligning markers. We then cannulated the distal aspect of the proximal graft and were able to successfully cannulate each of the small renal fenestrations extending out into the renal vessels with Glidewires.

Six-French Ansel flex sheaths were then advanced into the origin of both renal arteries. ICast 6x22 stents were then advanced into the origin of both renal vessels. Two stent links were left in the main body of the device. At this time, each renal stent was successfully deployed. A 10x20 mm angioplasty balloon was then used to complete the deployment at the very proximal end and anchor the stent in place.

The distal body was chosen and advanced via the right iliac artery. This was advanced with approximately one stent extending distally and successfully deployed down to the contralateral gate. The contralateral gate was successfully cannulated from the left iliac artery. We then completed our left iliac deployment using a 74x20 mm iliac limb. At this time, on the ipsilateral right side, the final two stents of the distal body were deployed, and we completed the deployment of the right iliac system using a 56x20 mm iliac stent. The Coda balloon was used for the junction between the components. At this time, a completion angiogram was performed. The superior mesenteric artery was patent as were both renal stents and renal perfusion. We angioplastied just distal to the renal stent deployment.

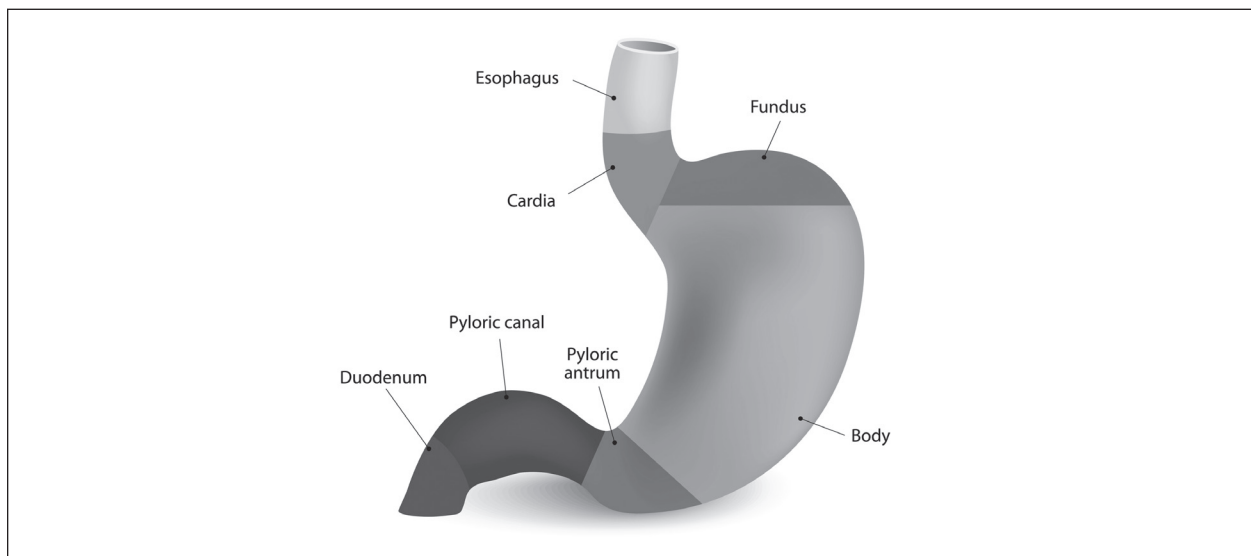
At this time, sheaths and wires were withdrawn. The arteriotomies were closed using 5-0 Prolene suture. The large hernia on the right inguinal area was reduced, and we used a mesh Bard plug placed and secured it anteriorly with Prolene suture. Each inguinal wound was then irrigated and closed with 2-0 Vicryl, 3-0 Vicryl, and 4-0 Monocryl subcuticular stitch.



Case 1: Gastric Bypass

FIGURE 6.1

Internal structure of the stomach



Discharge summary:

Patient is a 33-year-old black female with a lifetime history of morbid obesity (BMI 40.2) now complicated by hypertension, elevated cholesterol levels, and non-insulin-dependent Type 2 diabetes.

- Admitting diagnosis: Morbid Obesity, Hypertension, Hypercholesterolemia, NIDDM
- Discharge diagnosis: Same

Operation and procedure: Laparoscopic Roux-en-Y gastric bypass.

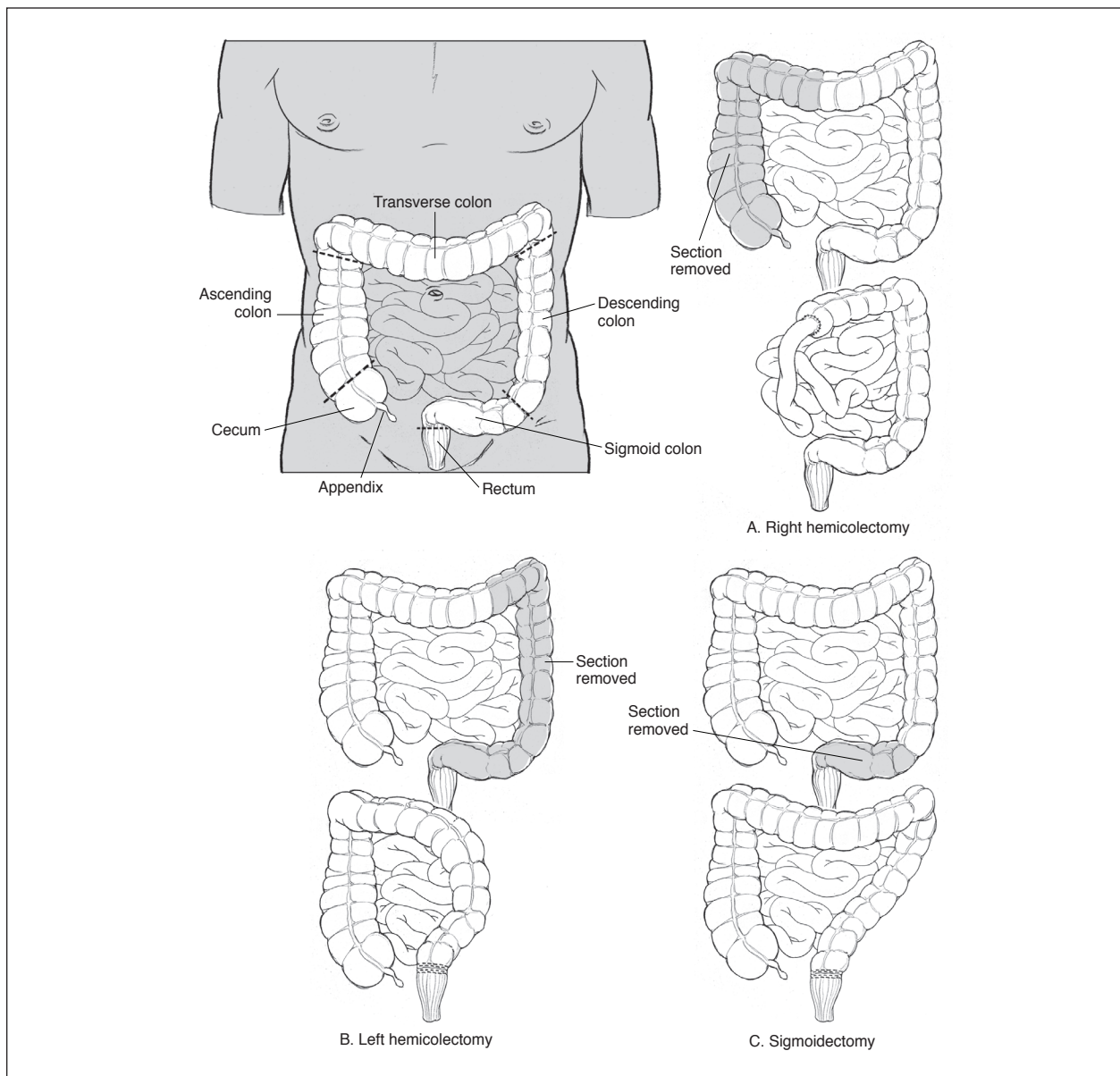
Hospital course:

This is a 33-year-old female, presented to the Bariatric Center for treatment of longstanding morbid obesity and associated comorbidities. Patient underwent standard bariatric consults,



Case 5: Exploratory Laparotomy/Colectomy

FIGURE 6.2 Colectomy



TS30ZZ

0L950ZX

0LWX07Z

Miscellaneous Cases Answers

0FBD3ZZ

0RP503Z

0L5J4Z

G3ZZ

01B20ZX

00T70ZZ

0TS30ZZ

07JT0

Answers to Case 1: Left Heart Catheterization

ICD-10-CM codes:

I21.4, non-ST elevation (NSTEMI) myocardial infarction

I25.10, atherosclerotic heart disease of native coronary artery without angina pectoris

ICD-10-PCS codes:

4A023N7, Measurement of cardiac sampling and pressure, left heart, percutaneous approach

B2111ZZ, Fluoroscopy of multiple coronary arteries using low osmolar contrast

Rationale:

Left heart catheterization is the passage of a thin flexible catheter into the left side of the heart. It is done to diagnose or treat certain heart problems. To find an ICD-10-PCS code, start by looking up “catheterization, heart.” The coder is directed to see Measurement, Cardiac 4A02. There are several cardiac options on this table (fourth character value of 2). Looking at the character 7 qualifier options will quickly help the coder to target the appropriate row on the table. In this case, the seventh character was 7 to indicate the left heart.

Many facilities will not hard code the fluoroscopy. If it is separately coded, the type of contrast used impacts code assignment.

Answers to Case 2: Femur Reposition

ICD-10-CM code:

S72.111A, displaced fracture of the greater trochanter of right femur, initial care for closed fracture

ICD-10-PCS code:

0QS606Z, Reposition of the right upper femur with intramedullary internal fixation device, open approach

Rationale:

A fracture not documented as displaced or non-displaced should be coded as displaced, per the *ICD-10-PCS Official Guidelines for Coding and Reporting*.

Per the ICD-10-PCS Body Part Key, the greater trochanter is considered the upper femur.

According to the *ICD-10-PCS Official Guidelines for Coding and Reporting*, B3.15, reduction of a displaced fracture is coded to the root operation Reposition.

Temporary post-op wound drains are considered integral to the performance of a procedure and not coded as devices, according to guideline B6.1b of the ICD-10-PCS guidelines.

Answers to Case 3: Excisional Debridement

ICD-10-CM codes:

E11.69, type 2 diabetes mellitus with other specified complication

M86.172, other acute osteomyelitis, left ankle and foot

E11.621, type 2 diabetes mellitus with foot ulcer

I50.23, acute on chronic systolic (congestive) heart failure

N17.9, acute kidney failure, unspecified

I13.0, hypertensive heart and chronic kidney disease with heart failure and stage 1 through stage 4 chronic kidney disease or unspecified chronic kidney disease

N18.3, chronic kidney disease, stage 3 (moderate)

L97.529, non-pressure chronic ulcer of other part of left foot with unspecified severity

ICD-10-PCS code:

0JBR0ZZ, Excision of left foot subcutaneous tissue and fascia, open approach

Rationale:

For diabetes coding, the word “with” should be interpreted to mean “associated with” or “due to” when it appears in a code title, the Alphabetic Index, or an instructional note in the Tabular List, per the *ICD-10-CM Official Guidelines for Coding and Reporting*. All manifestations under the subterm “with” in the Alphabetic Index can be interpreted as diabetic manifestations/ complications unless another causation is documented by the provider.

Per *Coding Clinic*, Third Quarter 2017, assign codes for Type 2 diabetes mellitus with foot ulcer (E11.621) and assign a code from category L97.- (non-pressure chronic ulcer of lower limb, not elsewhere classified) as an additional diagnosis.

For hypertension with heart and kidney involvement, assign codes from category I13.- (hypertensive heart and chronic kidney disease), additional codes from categories I50.- (heart failure) if heart failure is present, and from category N18.- (chronic kidney disease). The classification presumes a causal relationship between hypertension and heart involvement and between hypertension and kidney involvement, as the two conditions are linked by the term “with” in the Alphabetic Index. In addition to codes from categories I13.- and N18.-, a code should also be assigned for the acute renal failure (N17-).

Excisional debridement is defined as the surgical removal or cutting away of such tissue, necrosis, or slough and involves the use of a scalpel to remove devitalized tissue. Documentation of excisional debridement should be specific regarding the type of debridement. If the documentation is not clear or if there is any question about the procedure, the provider should be queried for clarification.

Per the *ICD-10-PCS Official Guidelines for Coding and Reporting*, for overlapping body layers, the body part specifying the deepest layer is coded for the root operation Excision. Additionally, if a body system does not contain a separate body part value for toes, procedures performed on the toes are coded to the body part value for the foot.

Clinical Scenario Workbook 2020 ICD-10-PCS Edition

JustCoding's Clinical Scenario Workbook: 2020 ICD-10-PCS Edition provides an opportunity for coders to practice and refine their skills in a hands-on way by using a wide range of real-life case scenarios. Coders will determine the correct ICD-10-CM and ICD-10-PCS codes to report for each case scenario based on provided documentation, evidence of sufficient medical necessity, and any conditions present that would allow for MS-DRG capture.

A full answer key with coding rationale for each case allows coders to self-audit and find immediate answers to their questions. When applicable, cases will also include references to guidance from the *2020 Official Guidelines for Coding and Reporting, Coding Clinic*, and the ICD-10-CM and ICD-10-PCS manuals.

These 52 case scenarios let coders practice real-world coding without risking actual revenue. Coders can practice on their own or as a group, with enough cases for coding teams to complete one each week together for a full year.

About Simplify Compliance

Simplify Compliance, with its three pillars of thought leadership, expertise, and application, provides critical insight, analysis, tools, and training to healthcare organizations nationwide. It empowers healthcare professionals with solution-focused information and intelligence to help their facilities and systems achieve compliance, financial performance, leadership, and organizational excellence. In addition, Simplify Compliance nurtures and provides access to productive C-suite relationships and engaged professional networks, deploys subject matter expertise deep into key functional areas, and enhances the utility of proprietary decision-support knowledge.

800-650-6787

www.hcmarketplace.com

**Simplify
Compliance**
Learn, Comply, Succeed

100 Winners Circle, Suite 300
Brentwood, TN 37027



JCCSICD10P20